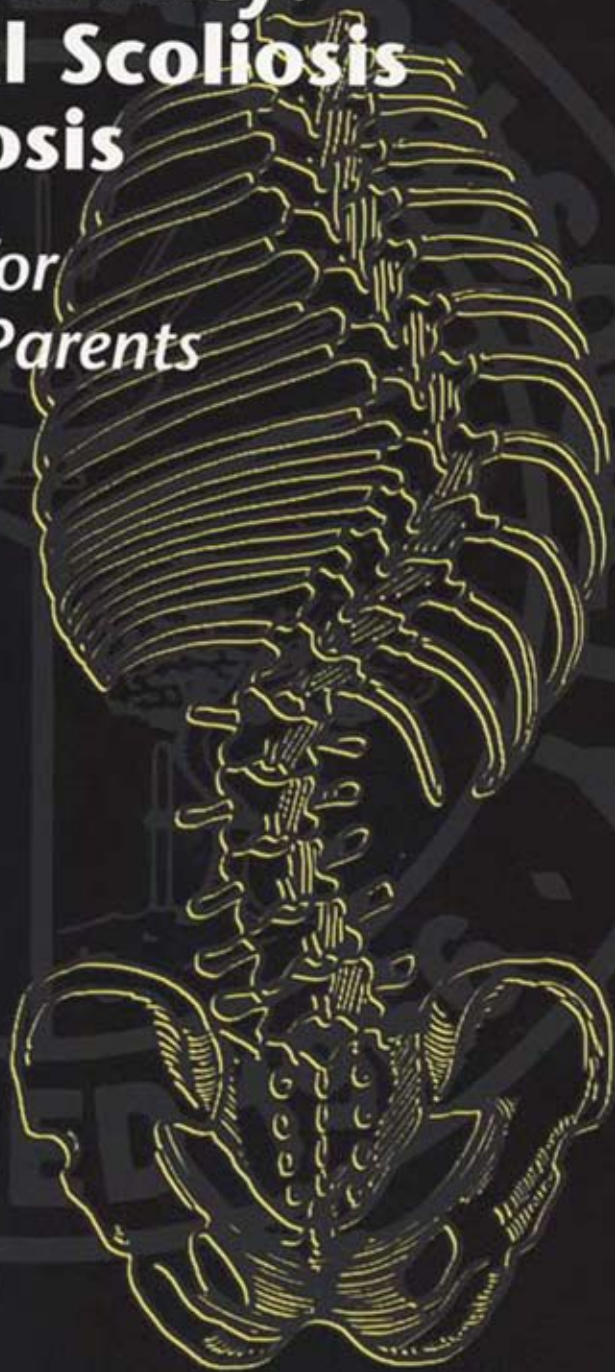


Spinal Deformity: Congenital Scoliosis and Kyphosis

*A Handbook for
Patients and Parents*



Published by:
**SCOLIOSIS
RESEARCH
SOCIETY**

Additional copies of this booklet
are available at cost from the
Scoliosis Research Society,
Milwaukee, WI 53202
414-289-9107
414-276-3349
Internet: www.srs.org

*Prepared by the Education Committee of
the Scoliosis Research Society
with assistance from Spine Research Associates*

Illustrations: Lauren Shavell, Medical Imagery

Preface

The Scoliosis Research Society has prepared this booklet to provide patients and /or their parents with a better understanding of a particular type of spine deformity—*congenital*, its diagnosis and treatment. This information is intended as a supplement to the information your physician will provide. The behavior of congenital spinal deformities may be very different from one individual to another though a number of general statements can be made. However, your orthopaedic surgeon will be the most important source of information for you or your child's particular case.

It is beyond the scope of this booklet to discuss in detail the technical aspects of all the various surgical procedures that may be needed. But, general concepts about the surgical treatment are discussed. Additionally, it must be stressed that congenital spinal deformities are much different than the more common idiopathic type of deformity, requiring different evaluation and treatment.

It is not intended that the contents of this manual be interpreted as standards or guidelines proposed by the Scoliosis Research Society.

What Is A Congenital Spinal Deformity?

These are spinal deformities—scoliosis (side-to-side) or kyphosis (excessive roundback)—that are caused by abnormally formed or joined vertebrae, which an affected person is born with. The type of deformity that is seen depends on which direction and where the abnormal vertebrae are positioned within the spinal column. The normal spine should be straight when viewed from behind (Figure 1a). When viewed from the side, there should be a gentle roundback (kyphosis) in the thoracic (chest part) spine and lordosis (swayback) in the lumbar (lower part) spine (Figure 1b). Scoliosis (Figure 1c) or increased kyphosis or lordosis (Figure 1d) are abnormalities and in congenital cases are caused by *asymmetric growth* of the abnormal vertebrae.

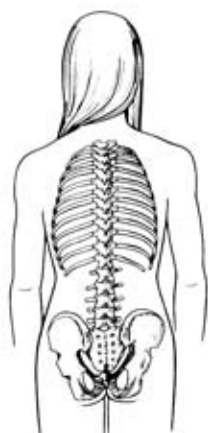

Fig. 1a

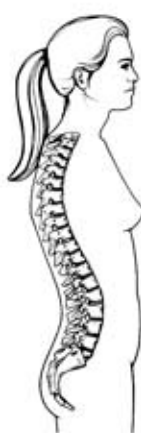

Fig. 1b

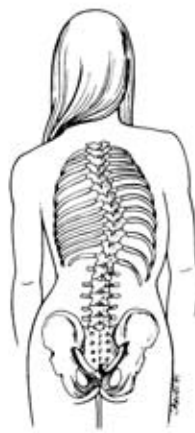

Fig. 1c

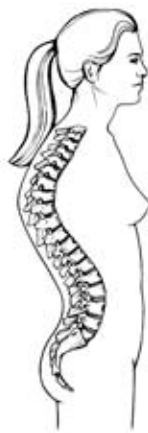

Fig. 1d

Figure 1a: Normal straight spine as viewed from behind

Figure 1b: Normal spine viewed from the side showing normal curvatures—kyphosis (roundback) in the thoracic spine and lordosis (swayback) in the lumbar spine.

Figure 1c: Abnormal spine viewed from behind showing scoliosis

Figure 1d: Abnormal spine viewed from the side showing excessive thoracic kyphosis and excessive lordosis

What causes the spinal deformity in those with abnormal vertebrae?

As mentioned above, the key factor causing the spine to curve is the *asymmetric growth* of the abnormally formed vertebrae. The abnormalities can be classified as: Type I—Failures of Formation (hemivertebrae or incompletely formed vertebrae) and Type II—Failures of Segmentation (vertebrae that are abnormally joined together). There also can be combination of the two (Figures 2a–c). A hemivertebra causes one side of the spine to grow more than the other. Vertebrae that are joined together on one side (unsegmented bar) result in tethering of the growth on that side, again causing the spine to curve. It is important to note that although the abnormal vertebrae are present at birth, there may not be much of an abnormal curvature at first. This occurs with growth. But even with growth, many of these affected spines may curve very little or not at all. In fact in spines with multiple abnormal vertebrae, the main effect may be significant stunting of trunk growth rather than increasing curvature. There may be very little increase in the curvature until the adolescent growth spurt.

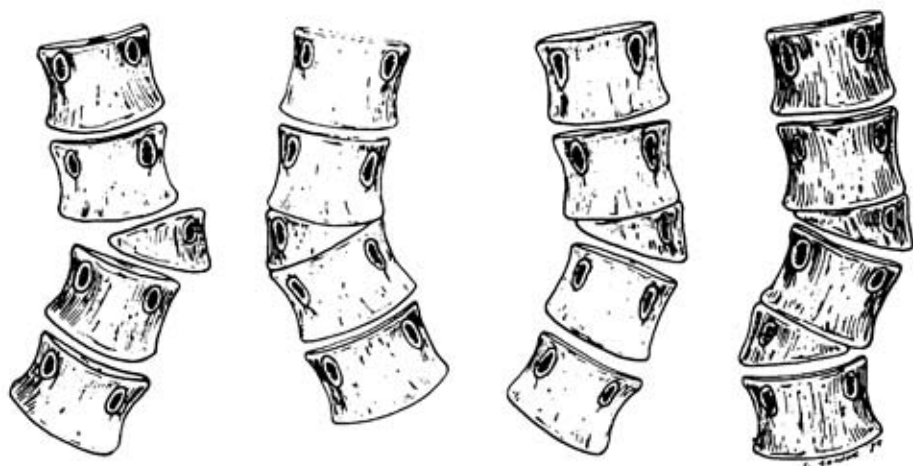

Fig. 2a

What Are the Signs of Congenital Spinal Deformity?

1. Side-to-side curvature or abnormal roundback or swayback.
2. Skin abnormalities on the back – hairy patches, dimples, discolored areas.
3. Abnormally formed or functioning arms or legs.
4. Abnormal functioning bowel and/or bladder.
5. Uneven shoulders, waist or hips.
6. Disproportionate length of the trunk to the legs.
7. Head not centered over the pelvis.
8. Hump(s) on the back that are seen when the person bends forward.

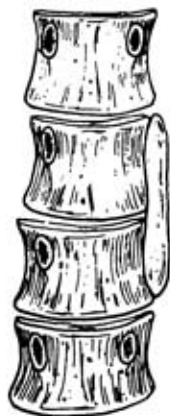

Fig. 2a

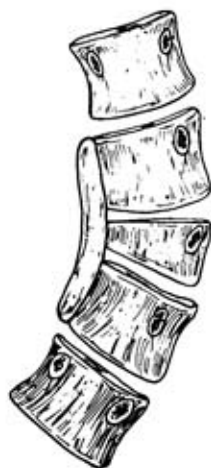

Fig. 2b

Figure 2a: Failures of Formation (hemivertebrae) of various type

Figure 2b: Failure of Segmentation (unilateral bar)

Figure 2c: Combination of Failure of Formation (hemivertebra) spanned by a Failure of Segmentation (unilateral bar)

Heredity and associated conditions and congenital spine deformity.

Congenital spinal deformities are generally not considered to be hereditary. However, congenital spinal abnormalities may be associated with other conditions that are. Therefore, ordinarily, parents of a child with an isolated congenital spinal deformity are not at increased risk for having another child with it. Currently, there is no way to prevent congenital spinal deformity and it is not entirely clear why these abnormalities occur.

Because of the events that occur during the development of the embryo and fetus a number of associated abnormalities can be seen with congenital spinal deformity. The most common are:

1. Klippel-Feil syndrome (congenital fusion of 2 or more vertebrae in the neck) – 25%
2. Kidney-bladder system abnormalities – 30%
3. Spinal cord abnormalities – 15%
4. Congenital heart problems – 12%
5. These abnormalities may or may not be functionally significant.

Additionally, congenital spinal deformities may be associated with various syndromes (e.g. VACTERL, Goldenhar, Fetal Alcohol) to name a few.

What should be done?

Proper diagnosis of the abnormality should be made as soon as it is recognized. This may involve special X-rays, MRI, ultrasound or other tests. The results of these studies help identify associated problems and provide information about how the spine deformity may behave in the future. Usually a period of what has been called “controlled observation” should occur also to see how the abnormality is behaving. This is done with periodic physical exams and X-rays. If steady increase in the curvature or other functional problems arise, the appropriate surgical procedure(s) should be undertaken.

One of the big differences between congenital and idiopathic deformities is that braces are *not effective* in congenital deformities. The only effective treatment is to eliminate or modify the asymmetric growth of the abnormal vertebrae most commonly accomplished by spinal fusion. The surgery may have to be done when a child is quite young in order to control a progressive deformity. Parents are understandably concerned that early fusion, which arrests growth of the spine within the fused segment, may lead to stunting of trunk growth. While this is true to an extent, trying to regain trunk height by correcting a very severe curvature after completion of growth is not possible and may be dangerous. Even if early surgery is done, additional procedures may be necessary if the original surgery does not completely control the curve. In actively growing children both anterior (in the front) and posterior (in the back) fusion may be necessary to control the deformity. These techniques can be applied to both scoliosis and kyphosis. Achieving a spinal fusion requires either autograft (a person's own) or allograft (someone else's) bone, a bone substitute or a combination of 2 or more of these sources.

Associated problems (e.g. spinal cord abnormalities) may require specific treatment either before, at the same time, or even after the surgical treatment for the spinal deformity. Sometimes, the spinal deformity itself may cause damage to the spinal cord (e.g. congenital kyphosis due to failure of formation) rather than an intrinsic spinal cord abnormality.

Treatment options

Controlled observation – This is accomplished by periodic physical exams and X-rays and is continued without specific treatment as long as no increase in the curve occurs and is continued until skeletal maturity. (It is also done after surgical treatment).

Surgical treatment – Currently all surgical procedures for the treatment of congenital spinal deformity involve fusion of at least 2 vertebrae. These operations may involve fusing the curve without correction (in situ fusion) with or without internal fixation (implanted rods, hooks, etc), correction of the curve with internal fixation plus fusion, removal of a hemivertebra with internal fixation, or fusion of the convex side of the curve only. As mentioned above, growing children often require anterior and posterior fusion to adequately control the curve. It is absolutely essential that the fusion heals, otherwise the procedure will fail and the curve will not be controlled. Newer procedures that do not involve a fusion are being developed but are considered experimental at this time. There are many factors that must be considered in choosing the best procedure for you or your child. The choices available should be discussed with your orthopaedic surgeon.

Post-operative casts or braces – Usually in children either a brace or cast will be used for a period of time after the surgery to help immobilize the spine so that the fusion heals properly. Braces can also help align and balance the adjacent and normal vertebrae which have been drawn into the curve. In older children and adults, rigid internal fixation may eliminate the need for a cast or brace.

Summary

Congenital spinal deformities are caused by the asymmetric growth of vertebral abnormalities that a person is born with. While some affected persons never develop a significant curvature, many do and the curvature may become very severe if not recognized and treated appropriately. A number of potentially important associated conditions can exist along with the congenital spinal deformity. Usually a period of observation is needed to assess the behavior of the deformity. If the deformity worsens, the only effective treatment is surgical. A number of operations can be done but at this time all involve fusing a segment of the spine. The surgery is performed when it has been determined that the curvature needs to be controlled, sometimes when a child is quite young. Continued observation until at least the end of growth is necessary for all patients with congenital spinal deformities.

Glossary of Medical Terms

Anterior fusion: fusion performed from the front of the spine by removing the discs and packing the disc spaces with bone graft

Allograft bone: bone obtained from another person

Autograft bone: bone obtained from the same person (pelvis, rib) and transferred to a different place in the body

Congenital spinal deformity: curvatures caused by abnormally formed vertebrae that a person is born with

Hemivertebra: an incompletely formed vertebra—a failure of formation

Internal fixation: rods, hooks, screws, wires and/or plates that are used to stabilize the operated part of the spine

Klippel-Feil syndrome: a congenital fusion of 2 or more vertebrae in the neck

Kyphosis: a curvature of the spine toward the back

Lumbar spine: lower spine between the chest and the pelvis

Posterior fusion: fusion performed from the back of the spine.

Thoracic spine: upper spine from the bottom of the neck to the last rib

Unsegmented bar: an abnormal connection between 2 or more vertebrae, usually on one side



SCOLIOSIS RESEARCH SOCIETY

Milwaukee, WI 53202

Phone: (414) 289-9107

Fax: (414) 276-3349

Internet: www.srs.org

Copyright © 2002, SCOLIOSIS RESEARCH SOCIETY